He mate niho ka kitea e te Rata

Management of common oral health problems seen in general practice

Key reviewers:
Dr Pauline Koopu, Te Whānāu-a-Apanui, Ngāti Konohi, Ngāti Kahu, Te Ao Marama (Māori Dental Association), Wellington

Dr Dorothy Boyd, Specialist in Paediatric Dentistry, Senior Dental Officer, Otago DHB

Ka kata a Kae – Kae laughs.

This is from the story of Tinirau and Kae, where Kae eats Tinirau's pet whale. Tinirau sends some women to exact revenge. In order to identify Kae, they have to make him laugh to see his crooked teeth.

www.bpac.org.nz keyword: oralproblems

Patients may present to their GP with oral health problems. When necessary, treatment may need to be initiated followed by appropriate referral to a dental service. Good oral health behaviours should be emphasised (see page 20).

Poor oral hygiene and gum disease

Halitosis or bad breath can indicate a number of oral health and general medical conditions. Check the mouth (teeth, gums and tongue) for an obvious dental cause such as bacterial buildup on the tongue and consider other factors such as diet. Some medical conditions associated with halitosis include sinus infection (post nasal drip), tonsillitis, respiratory infection, diabetes and oral cancers.



Figure 1: Gingivitis in a child. Note the redness around the gingival margin of the upper incisor teeth. (Source: D. Boyd)

Gingivitis is localised inflammation of the gums (Figure 1). Symptoms include swollen bleeding gums with brushing or flossing, erythema and halitosis but not usually pain.[1] For treatment and prevention, good oral hygiene should be followed. Appropriate use of an antiseptic mouth wash such as chlorhexidine gluconate 0.2% (Orion brand fully subsidised) may also assist (see page 22 for appropriate use). If applicable, smoking cessation should be advised.

Periodontitis is the loss of supportive bone structure around the root of the teeth caused by chronic gingivitis.[1] Symptoms include receding gums that bleed easily on contact and subgingival dental plaque. Referral for mechanical debridement and ongoing dental care is required. Periodontal disease is rarely a feature of systemic disease.

Kawakawa for dental pain

Kawakawa (*Macropiper excelsum*, Māori Pepper Tree) is a traditional Rongoā Māori treatment used for toothache. The leaves, which have a spicy taste, are chewed and retained in the mouth, while the saliva is swallowed.

Kawakawa is related to the black pepper tree and kava. The leaves contain the essential oil myristicin, which is also the predominant psychoactive ingredient in nutmeg, although kawakawa is not used for psychotropic purposes.

There have been no scientific studies on the biological activity or toxicology of kawakawa, however no adverse effects or interactions have been recorded.



Medical problems associated with oral health problems

- Dry mouth (xerostomia) – e.g. from Sjögren's syndrome or from adverse effects of medication, head and neck radiotherapy
- Gingival hyperplasia (hypertrophic gums) can be an adverse effect of calcium channel blockers or cyclosporin and some antiepileptic medications.
- Oral cancers
- Poor nutrition
- Mental health problems, visual impairment or lack of knowledge leading to poor oral hygiene and inadequate diet
- Parkinson's disease leading to difficulties with chewing and dental hygiene
- Eating disorders e.g. Bulimia – associated with erosion of tooth enamel particularly of the palatal (roof of mouth) surface of upper teeth
- Poorly controlled diabetes may result in oral health problems
- Osteonecrosis of the jaw related to bisphosphonate therapy

Other causes of "dental" pain

Trigeminal neuralgia

Herpetic neuralgia

Referred pain from tempo-mandibular joints

Salivary gland disorders

Sinusitis

Jaw pain referred from mycocardial tissue or temporal arteritis

Neoplasia e.g. breast secondaries in jaw

Pericoronitis is an acute localised infection under the gum flaps of a partially erupted tooth or impacted tooth. This most commonly affects the wisdom teeth.[1] Initial treatment is irrigation of the area to remove debris (e.g. trapped food particles), chlorhexidine mouthwash and adequate analgesia. If the infection involves the wisdom teeth bilaterally and the swelling is marked, there can be airway compromise, requiring urgent hospital referral. If there is significant swelling or evidence of cellulitis or systemic disease, amoxycillin (500 mg three times per day, for five days) or metronidazole (400 mg three times per day, for five days), may be prescribed.

Dental caries is a disease caused by bacteria which damage hard tooth structure (also known as tooth decay or cavity). It is asymptomatic in the initial stages. If left untreated, the patient will usually start to notice temperature sensitivity and mild pain. Preventative education and dental treatment is required.

Sensitive teeth may be caused by periodontal disease, caries, trauma, toothbrush abrasion, erosion or attrition, age, smoking and medical conditions (e.g. radiation therapy). Patients often experience acute localised pain while eating and drinking cold foods/liquids. Toothpastes specially formulated for sensitive teeth can be used. Several applications may be required before sensitivity is reduced. Dentists can also apply desensitising agents. It is also important to eliminate any possible etiological disease.

Dental infection or abscess

All people with dental abscess require referral for further dental care such as root canal treatment or extraction (Figure 2). Treatment of acute symptoms can be managed in general practice.

If pain is significant, prescribe adequate and regular analgesia – begin with paracetamol or ibuprofen which can be taken together if pain relief, with either alone, is insufficient. If pain relief is still not adequate, add codeine. Patients can be advised to consume cool, soft foods.



Figure 2: Treatment for buccal abscess in a child, requiring general anaesthesia. Note the raised swelling buccal to the lower right first primary molar. This child was four years old and had a total of ten teeth restored or extracted. When small children have large amounts of work required, a general anaesthetic can be necessary. (Source: D. Boyd)



Figure 3: X-ray showing the relationship of the permanent teeth to the primary teeth. This demonstrates how trauma to primary teeth can cause damage to permanent teeth. (Source: D. Boyd)

If there are signs of severe infection (cellulitis, diffuse, tense, painful swelling of the infected tissues) or the patient is systemically unwell, prescribe amoxycillin (500 mg three times per day, for five days) or metronidazole (400 mg three times per day, for five days).[2,3]

If the patient has severe cellulitis, they may require hospital admission for intravenous antibiotics and fluids, or emergency referral if swelling poses a serious risk to general health (e.g. a compromised airway). In rare cases, cavernous sinus thrombosis may be a late complication of dental abscess or infection.

If there is marked swelling, the patient is in extreme discomfort or if dental care is not able to be accessed straight away (e.g. over a weekend), the abscess may be lanced and drained, using topical anaesthesia (or freezing with ethyl chloride spray). Incisions usually epithelialise rapidly, causing the abscess to fill with pus again, so it is important to follow-up with a hot, salty mouthwash to encourage continued drainage.

Toothache without abscess

Pulpitis is inflammation of the dental pulp. This usually arises from caries but can be caused by dental erosion or trauma. In the early stages pulpitis can be reversible after appropriate dental treatment (removal of carious tissue or protection of the pulp and restoration). The pain is usually moderate and the episode that results in the patient presenting for care may be preceded by other less acute episodes, pain on chewing and temperature sensitivity. If the inflammation continues without appropriate dental treatment, the pulp can be irreversibly damaged and root canal therapy or extraction may be required. The pain of irreversible pulpitis becomes severe, spontaneous, and persistent and often poorly localised. Prescribe adequate analgesia (see previous) and refer for dental care. Antibiotics are not indicated in the absence of cellulitis.[2,4]

Trauma

Trauma to teeth

Trauma causing tooth loss is common, especially in children and can result in fracture of teeth (or jaw), tooth

loosening or tooth loss (avulsion). All patients with tooth trauma require dental referral and radiography.[2] Tetanus injection may be required in some circumstances. Prophylactic antibiotics (amoxycillin) are only required in some cases of tooth avulsion.

Ensure that ACC information is completed. In the case of non-accidental trauma, injuries need to be appropriately documented and history recorded (see side bar). Injuries to primary teeth may cause damage to permanent successor teeth.

Non-accidental trauma

Oro-facial injuries occur commonly in cases of non-accidental injury. Reports of suspected child abuse can be made to the Child Youth and Family Service – 0508 FAMILY (0508 326459). Alternatively, and for suspected abuse in adults, contact the police.

The role of the doctor (or dentist) in this situation is to observe, document and report the injuries. Support should be offered, but an in-depth interview of the victim to confirm whether or not abuse has occurred should not be attempted, as this is the responsibility of the social worker or police officer.

Documentation should be specific and objective and should include:

- The time and date and who was present
- A verbatim account of the incident, including child/parent/caregiver statements
- A description of injuries, including diagrams if appropriate
- A note of any physical or behavioural anomalies
- An account of any advice sought on the matter e.g. from colleagues
- An account of subsequent action taken e.g. call to Child Youth and Family Services
- Planned follow-up and management of injuries

Treatment of an avulsed tooth[2,4]

The preferred emergency treatment of an avulsed permanent tooth is immediate re-implantation, ideally within five minutes (and up to 15 minutes). If rinsing is needed, use normal saline and also flush out any clot from the socket before the tooth is re-implanted. Touching, rubbing or cleaning of the root should be avoided as this reduces the likelihood of successful re-implantation. Hold the tooth by the crown. Look at the adjacent teeth to gauge the line/angle of the replaced tooth. The tooth can be held in place by gently biting on a piece of gauze. The patient should then be immediately referred to a dentist. Primary (deciduous) teeth should not be re-implanted as doing so may damage the permanent tooth above (Figure 3).

If the tooth is unable to be put back in, the patent should be referred immediately to a dentist and the tooth transported in the patient's mouth, under the top lip (but the risk of swallowing the tooth must be considered, especially in children), or placed in a container with fresh, cold milk or saline (do not use water).

Post dental procedures

"Dry socket" – acute alveolar osteitis is seen in patients who have a history of extraction in past 24 – 48 hours, and present with severe, persistent throbbing pain that is localised to the socket. The socket is usually very tender to palpation and there is no blood clot visible. There may be associated halitosis. A dry socket is more frequently seen in people who smoke, especially if they have not abstained since extraction. Initial treatment is to examine the socket for debris and then irrigate with sterile saline. Antibiotics are not indicated but analgesics may be required.[4,5] The patient can be referred to a dentist for packing of the socket.

Post extraction haemorrhage is usually able to be stopped with a few minutes of local pressure on the bleeding socket with a gauze swab or pack.[4,6] This also applies to patients who may be taking aspirin or NSAIDs.[4] If the bleeding continues then refer for further dental care. Ideally this type of problem should be dealt with by the dentist who

performed the procedure, and the patient would normally be provided with written instructions on post extraction care.[6] A thorough review of the patient's medical history should be taken to rule out a haematological disorder.

Lip bite post local anaesthetic is commonly seen in children. Significant trauma may be caused by a child chewing on a numb lip.

Teething in infants

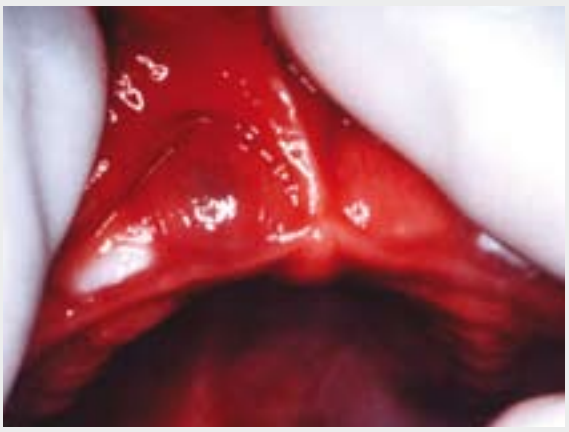

Figure 4: This is an eruption cyst, seen reasonably commonly in infants who are teething. It does not require treatment. (Source: D. Boyd)

Prophylactic antibiotics for prevention of bacterial endocarditis

New Zealand National Heart Foundation guidelines recommend antibiotic prophylaxis should be given to those at highest risk of adverse outcomes, undergoing dental procedures that involve manipulation of either gingival tissue or the periapical region of teeth or perforation of the oral mucosa. The recommended antibiotic is amoxycillin 2 g (child: 50 mg/kg up to 2 g) as a single dose one hour before the procedure.[7]

Cardiac conditions for which endocarditis prophylaxis is recommended:

- Prosthetic heart valves (bio or mechanical)
- Rheumatic valvular heart disease
- Previous endocarditis
- Unrepaired cyanotic congenital heart disease (include palliative shunts and conduits)
- Surgical or catheter repair of congenital heart disease with six months of repair procedure

For people with cardiac conditions, an important goal is prevention of dental caries and periodontal disease. Education and regular dental examination to detect disease, or risk of disease at an early stage, is ideal.

References:

1. Nguyen D, Martin J. Common dental infections in the primary care setting. Am Fam Physician. 2008;77(6):797-802.
2. Douglass A, Douglass J. Common dental emergencies. Am Fam Physician. 2003;67:511-6.
3. Clinical Knowledge Summaries (CKS). Dental abscess management. Available from www.cks.nhs.uk (Accessed June 2009).
4. Kingon A. Solving dental problems in general practice. Aust Fam Physician. 2009;38(4):211-6.
5. Mansour M, Cox S. Patients presenting to the general practitioner with pain of dental origin. Med J Aust 2006;185(2):64-7.
6. Patel K, Driscoll P. Dental knowledge of accident and emergency senior house officers. Emerg Med J. 2002;19:539-41.
7. National Heart Foundation of New Zealand (NHF). Guideline for the prevention of infective endocarditis associated with dental and other medical interventions. NHF 2008. Available from www.nhf.org.nz (accessed June 2009).