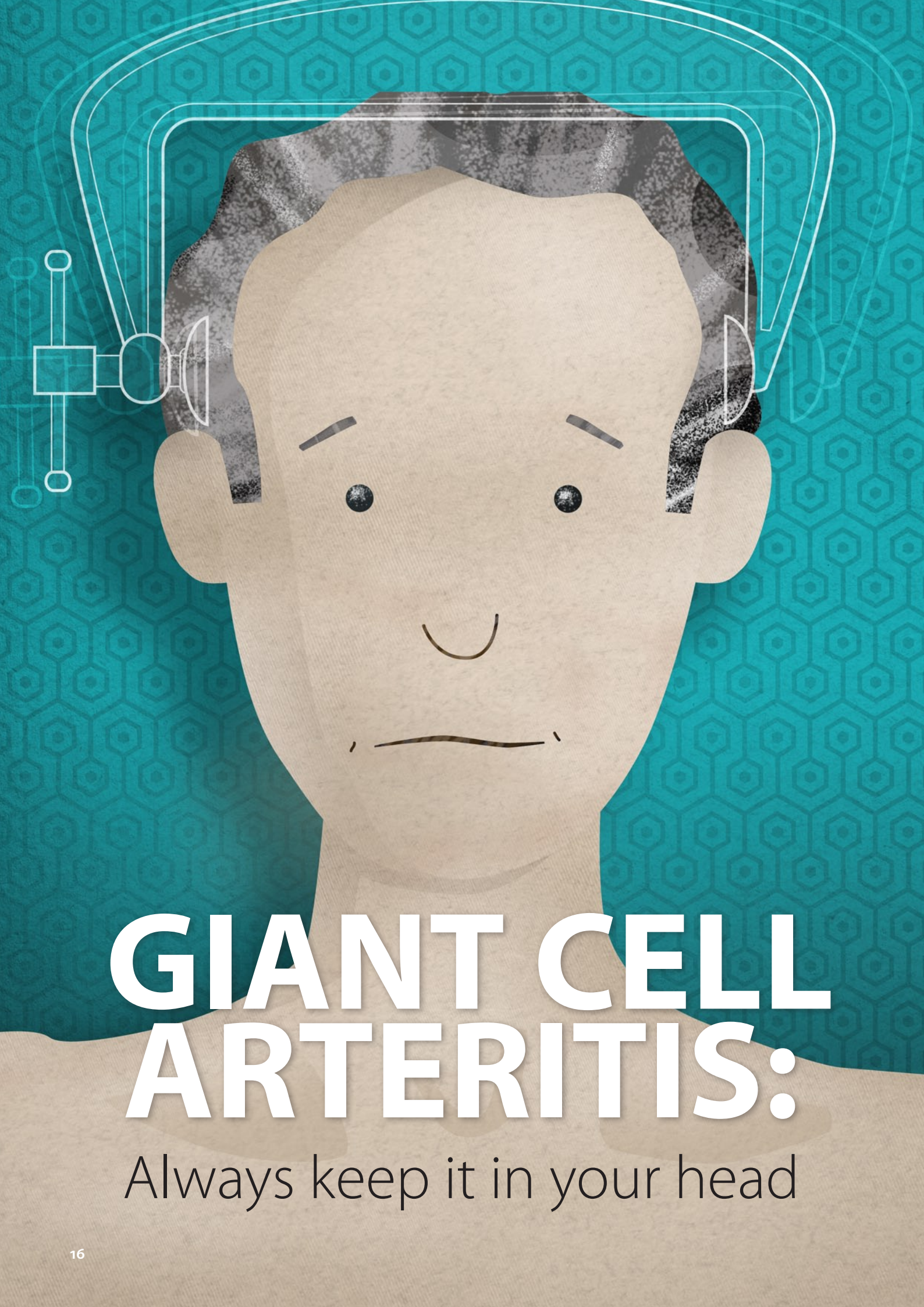

GIANT CELL ARTERITIS:

Always keep it in your head

Giant cell arteritis, also referred to as temporal arteritis, is a form of vasculitis which predominantly affects older people. It must be treated urgently, as it is associated with a significant risk of permanent visual loss, stroke, aneurysm and possible death. A low threshold for suspicion and prompt corticosteroid treatment are essential to prevent these complications. However, arriving at a diagnosis of this enigmatic condition can be difficult, as patients can present with non-specific symptoms. Referring the patient for a temporal artery biopsy is a key aspect of confirming the diagnosis, but this must not delay the initiation of corticosteroid treatment if giant cell arteritis is suspected.

A headache not to miss

Giant cell arteritis is an immune-mediated, ischaemic condition caused by inflammation in the wall of medium to large arteries. While it can affect all medium to large arteries in the head, neck and upper torso, the involvement of the temporal artery is usually the only artery in which physical changes are clinically apparent (giving rise to the alternative name of temporal arteritis). It is the most common form of vasculitis in adults.¹

Giant cell arteritis usually affects people aged over 50 years,² and is only rarely seen in younger people. It is most prevalent in Caucasians, particularly of Northern-European (e.g. Scandinavian) descent, and is two to three times more common in females than males.³ Worldwide, incidence ranges between 10 – 20 cases per 100 000 people aged over 50 years.³ A New Zealand study found a similar local incidence of 12 cases per year, per 100 000 people aged over 50 years.⁴


Symptoms of giant cell arteritis include headache, scalp tenderness, jaw claudication or other orofacial pain, neck or shoulder pain, visual disturbances and systemic symptoms, such as sweats, fever and anorexia. There may be palpable changes to the temporal artery on examination. An acute phase response is usually seen on laboratory assessment, and a temporal artery biopsy will show inflammation and multinucleated cells with involvement of the internal elastic lamina.

If undetected, giant cell arteritis can result in catastrophic sequelae, such as irreversible visual loss, stroke and aortic aneurysm. Visual loss, due to ischaemic optic neuropathy, is an early manifestation and can be a presenting symptom. This occurs in 20 – 50% of people with giant cell arteritis if they are untreated.^{5,6} Large-vessel stenosis, and with it an increased risk of stroke, occurs in 10 – 15% of people.^{7,8} Prompt treatment with corticosteroids can markedly reduce these risks. For example, the likelihood of visual loss decreases from 20% to 1% in patients with no preceding visual loss once treatment is initiated.⁷ Patients who already have some visual loss at the initial presentation, however, have a poorer prognosis. One-quarter of patients develop further visual deterioration in the same eye, and up to 10% lose vision in the other eye, usually within the first few days, despite treatment.⁹

Giant cell arteritis should be strongly considered in older patients presenting with a new type of headache, jaw pain or visual disturbances (also see: “Making a diagnosis”, over page). Whenever there is a reasonable suspicion of the condition, discuss the patient with an Ophthalmologist or Rheumatologist (depending on local guidelines/protocols) to organise referral for a temporal artery biopsy, and initiate same-day treatment with corticosteroids. Where there is a strong clinical suspicion of giant cell arteritis, a delay in treatment will almost always have greater consequences than an unnecessary dose of corticosteroids in someone who is later found to not to have the condition.

The link with polymyalgia rheumatica

Giant cell arteritis is closely associated with polymyalgia rheumatica, although the link between the two conditions is complex and not completely understood.¹⁰ They are considered by some researchers to be different manifestations of the same underlying disease process.^{3,5} Both conditions are likely to be encountered in primary care, but polymyalgia rheumatica is significantly more common. Approximately 40 – 60% of people with giant cell arteritis have concurrent polymyalgia rheumatica.⁵ Conversely, 16 – 21% of people with polymyalgia rheumatica will develop giant cell arteritis.⁵ Overlapping symptoms and risk factors, and the effect of polymyalgia rheumatica and corticosteroid treatment on inflammatory markers, can make the identification of giant cell arteritis more challenging in a person with polymyalgia rheumatica.

 For further information, see “Polymyalgia rheumatica”, page 24.

Pathology and aetiology: how does it happen?

In people with giant cell arteritis, inflammation, caused by an immune reaction, occurs within the arterial wall. The inflammation is often irregular and is characterised by a granulomatous inflammatory infiltrate with the presence of large, macrophage-induced multinuclear cells - the “giant cells” in giant cell arteritis.^{3,7} This leads to a protective response from the arteries, resulting in myofibroblast proliferation, new vessel formation and thickening of the artery walls, culminating in potential infarction.³

The underlying cause of giant cell arteritis is largely unknown, but both genetic and external factors, e.g. infections, are thought to play a role.³

Making a diagnosis of giant cell arteritis

Giant cell arteritis is diagnosed by identifying risk factors from the patient’s history and red flags from their clinical presentation, followed by laboratory assessment and referral for a biopsy of the temporal artery. Most symptoms in people with giant cell arteritis will develop gradually over one to two months, although rapid onset is possible.

The most significant risk factors for giant cell arteritis are:^{2,7}

- Age > 50 years
- A previous or current diagnosis of polymyalgia rheumatica
- Female gender
- European ethnicity

The patient’s description of their symptoms

Specifically enquire about the following symptoms:

- Headache
- Scalp pain or tenderness
- Jaw claudication
- Visual symptoms

Abrupt onset of headache is the most frequent symptom of giant cell arteritis, and will be present in approximately 75% of cases.^{2,11} Any new onset or new type of headache in a person aged over 50 years should be considered a red flag. In giant cell arteritis, the headache is typically unlike a normal headache for the patient, and may be described as “head pain”.¹⁰ It is commonly unilateral, with a constant pain that may be severe enough to disturb sleep.¹⁰ It is usually centred over the temporal or occipital area.¹² Occasionally the pain will be bilateral and diffuse.

Scalp pain or discomfort occurs in approximately one-quarter of patients with giant cell arteritis.^{5,10} The patient may report pain when brushing their hair or when resting their head on a pillow.

Systemic features, including low-grade fever, anorexia and fatigue, are present in approximately half of patients.^{5,12} Giant cell arteritis may also be associated with weight loss and night sweats, however, these symptoms may also suggest other possible diagnoses, such as a malignancy.¹⁰ In rare instances, systemic symptoms will be the only clinical indication of giant cell arteritis, therefore, the diagnosis of giant cell arteritis should be considered in any patient with systemic symptoms, raised inflammatory markers and no evidence of another cause, such as infection.

Jaw claudication in the muscles of the tongue and jaw, e.g. while chewing, occurs in approximately one-quarter of people with giant cell arteritis.^{4,7} In severe cases, this may lead to numbness or infarction of the scalp or the tongue. It is important to specifically ask patients about jaw claudication, as patients may not connect this with their headache or other symptoms. Pain while chewing and the presence of jaw claudication strongly indicates giant cell arteritis. Distinguishing between jaw pain from other causes (such as temporomandibular joint dysfunction) and true jaw claudication is important – the pain in jaw claudication is a cramping pain occurring after prolonged chewing or talking.

Visual symptoms are less common at initial presentation, but are of critical importance. Symptoms may include transient loss of vision in one eye, blurring and diplopia.¹² Complete loss of vision can also occur.¹²

Limb claudication, particularly in the arms, may also be present, but is a rare finding.¹¹ It may indicate large-vessel giant cell arteritis (i.e. outside the cranial vessels).⁵

What to include in the examination

The clinical examination should include assessment of:

- Temporal arteries
- Visual acuity
- Pupillary response to light
- Neurological signs
- Peripheral pulses, blood pressure and bruits

Examine the temporal artery and its branches for unusual prominence and erythema.¹⁰ On palpation these vessels may be thickened, hardened, nodular, beaded or have reduced or

absent pulses.¹² Tenderness may be present on the scalp or over the vessels. A normal temporal artery, however, does not exclude giant cell arteritis.¹²

An eye exam should be performed, and should include visual acuity (using corrective distance glasses if the patient has them, and excluding any residual refractive error using a pinhole), the pupillary light reflex, visual field testing by finger confrontation and fundoscopy.¹² With optic nerve involvement, the pupillary light reflex may be sluggish or absent, and a swinging light test may indicate a relative afferent pupillary defect (the patient's pupils fail to contract, and therefore appear to dilate, when a light is swung from the unaffected eye to the affected eye).¹² Fundoscopy may reveal swelling or pallor of the optic disc with associated haemorrhage.⁵

A brief, but focused neurological exam should be performed depending on the patients presenting symptoms. Neurological manifestations can occur in one-third of patients with giant cell arteritis, most commonly cranial nerve palsies, peripheral neuropathies and, rarely, strokes in the region of the carotid or vertebrobasilar artery.⁵

Perform auscultation over the carotid, subclavian, axillary or brachial arteries as bruits can be present and may indicate large-vessel involvement. Asymmetry of blood pressure or pulses in the neck and arms may be present, and can indicate large-vessel stenosis.¹² Auscultation over the patient's chest may reveal secondary aortic regurgitation (sometimes audible as a soft, high-pitched diastolic murmur best heard over the upper left sternal edge) from a thoracic aortic aneurysm, which can occur as a late complication in people with giant cell arteritis.⁵

Laboratory investigation

If the patient's risk-factors, symptoms and signs suggest giant cell arteritis the following tests should be urgently requested at the initial presentation:⁷

- C-reactive protein (CRP)
- Erythrocyte sedimentation rate (ESR)
- Full blood count (FBC)
- Liver function tests (LFTs)

While ESR and CRP are no longer routinely requested together for most conditions, either marker (or both) can be raised in giant cell arteritis and given the significant potential for morbidity in people with giant cell arteritis, it is recommended that both are requested in the initial presentation. This is consistent with most guidelines, as combining the two tests

marginally increases the sensitivity and specificity.^{5, 12} Any elevation of CRP or ESR is suggestive of giant cell arteritis in a patient with signs and symptoms, although, typically, in acute cases, levels are significantly elevated.² A normal CRP or ESR does not exclude giant cell arteritis; up to 20% of people with confirmed giant cell arteritis have only mildly raised inflammatory markers and a small number of patients will have levels within normal ranges on at least one of the tests.^{5, 10} If both CRP and ESR are normal, the likelihood of giant cell arteritis being present is reduced, but cannot be ruled out.

A full blood count in people with giant cell arteritis will typically indicate anaemia with a mild leukocytosis and an elevated platelet count.⁵

Liver function tests commonly indicate mildly elevated transaminases and alkaline phosphatase.⁵

Creatinine and electrolytes should also be tested (but do not need to be urgent) to provide a base-line for monitoring in people who are likely to be treated with long-term corticosteroids.

Imaging investigation

Imaging tests may be requested in secondary care, after referral, if there is a suspicion of large-vessel involvement. Ultrasound, computed tomography (CT) and magnetic resonance angiography are the most commonly used imaging techniques.

Differential diagnosis

The most important differential diagnoses to consider in patients with symptoms suggestive of giant cell arteritis include:^{7, 12}

- Migraine, intracranial haemorrhage and other causes of headache
- Herpes zoster
- Ear, nose and throat conditions, e.g. temporomandibular joint disorder, sinusitis
- Transient ischaemic attack
- Connective tissue diseases
- Cervical spine disease, e.g. spondylosis, radiculopathy causing cervicogenic headaches
- Other causes of acute visual loss, e.g. central retinal artery occlusion, non-arteritic ischaemic optic neuropathy
- Systemic vasculitides, e.g. Takayasu's arteritis (rare)
- Other significant intracranial pathology, e.g. infiltrative retro-orbital or skull lesions

The management of giant cell arteritis

If the findings from the history and examination strongly indicate giant cell arteritis, after considering possible differential diagnoses, urgent treatment and referral should be initiated. The first steps for most patients should be to provide a prescription for corticosteroids and to contact either an Ophthalmologist or Rheumatologist (depending on local referral criteria) to organise a temporal artery biopsy.

Organise a referral for biopsy

Urgent referral, i.e. within one week, to hospital for biopsy and an assessment of vision is required.¹² If the patient has symptoms of ischaemia, such as visual loss or diplopia, with or without jaw claudication, immediate referral is recommended as these features can indicate the rapid development of permanent visual loss.

The need for biopsy should never delay treatment. A biopsy can usually still be performed and provide accurate results two to six weeks after initiating corticosteroid treatment,¹² although it should ideally be performed within one week.

Give corticosteroids

Most guidelines recommend oral prednisone 40–60 mg, once daily, for patients with giant cell arteritis, with the higher dose used in patients with ischaemic symptoms.^{2, 12} In practice, as it can be difficult to rule out the presence of ischaemic involvement in primary care, a dose of 60 mg, once daily, should be used in most patients with suspected giant cell arteritis, and if necessary this can be adjusted once the patient has been assessed in secondary care. It is recommended that the prednisone dose is not less than 0.75 mg/kg, therefore a higher dose, e.g. up to 80 mg, may be given to a larger patient.

For patients who already have visual loss symptoms, consult with the Ophthalmologist or Rheumatologist about the possibility of intravenous corticosteroid treatment. Methylprednisolone (e.g. 1 g IV, daily, for three days) may be used in patients with visual loss at presentation or rapidly developing visual symptoms in order to halt their progression, however, evidence that this approach to treatment is more effective is limited.


The first dose of prednisone should be taken as soon as reasonably possible. The response to treatment is usually rapid, with resolution of most symptoms occurring within several days of starting the medicine. Therefore, a lack of response is

a strong indication that the initial diagnosis may have been incorrect.¹²

The initial dose of prednisone should be maintained for four weeks, or longer if symptoms and laboratory abnormalities remain.¹² Given the significant risk of morbidity associated with a relapse of giant cell arteritis, the prednisone tapering regimen must be slow and cautious. Dose reduction intervals can be lengthened, based on the patient's symptoms and history of relapses with previous dose reductions. A treatment duration of at least one to two years, often longer, should be expected.

As a general guide, the British Society for Rheumatology suggests that the daily dose of prednisone is tapered as follows:²


- Maintain the initial dose (40 – 60 mg) for at least four weeks, then;
- Reduce by 10 mg, every two weeks, down to 20 mg, then;
- Reduce by 2.5 mg, every two to four weeks, to 10 mg, then;
- Reduce by 1 mg, every four to eight weeks, provided there are no relapses

 For further information on tapering long-term corticosteroids and adverse effects, see "Polymyalgia rheumatica", Page 24.

Additional treatment

Aspirin, 100 mg, daily,* should be considered for patients without contraindications as there is some evidence that it decreases the rate of visual loss and other cerebrovascular complications.^{2,12}

Vitamin D supplements and advice to maintain adequate calcium intake should be given to all patients in order to limit the adverse effects of long-term prednisone treatment.¹³ Bisphosphonates should be prescribed to all patients with evidence of reduced bone-mineral density.⁵

 For further information on the bone sparing treatment in people treated with long-term corticosteroids, see "Polymyalgia rheumatica", Page 24.


A proton pump inhibitor (PPI), such as omeprazole may be considered for people who experience adverse gastrointestinal effects when taking prednisone, particularly when a NSAID is taken concurrently.¹³

* Most guidelines recommend 75 mg daily, however, this dose formulation is not subsidised in New Zealand.

What is a temporal artery biopsy?

A temporal artery biopsy involves removing a small section of the temporal artery. The surgery is performed as a minor procedure with local anaesthesia.

Due to the patchy inflammation that may be present (termed skip lesions), a minimum of 25 mm of the temporal artery is biopsied to reduce false-negative results; a biopsy on the contralateral artery may be considered if the results of the first biopsy are normal in a patient with strongly suspected giant cell arteritis. The biopsy will be negative in up to 10% of people with giant cell arteritis even with these measures, and a negative result should never be considered final if there are signs and symptoms in conjunction with other laboratory findings that continue to suggest the diagnosis.¹²



Follow-up and monitoring

A follow-up consultation should be scheduled to ensure there are no signs or symptoms of relapse of giant cell arteritis, and to monitor the adverse effects of corticosteroid treatment. The first follow-up appointment should be scheduled within a few days of the initial consultation. Further follow-ups should be scheduled one, three and six weeks later.¹² Follow-up appointments should then occur once every three months, for the duration of corticosteroid treatment.¹²

Advise the patient to return if symptoms of giant cell arteritis or corticosteroid-related adverse effects occur between visits.²

Each visit should include an assessment for any residual symptoms, a brief physical examination of the patient and consideration given to testing:^{2,7}

- CRP
- FBC
- HbA_{1c} (fasting serum glucose should be used for the first two months of treatment, as the rise in blood glucose levels due to corticosteroid use is too rapid to be accurately measured with HbA_{1c})
- Creatinine and electrolytes (to monitor the potential adverse effects of steroid treatment)

If CRP was normal, and ESR raised, when giant cell arteritis was diagnosed, monitoring ESR instead of CRP may be more appropriate.

Chest x-ray and abdominal ultrasound to assess for thoracic and abdominal aortic aneurysm is recommended annually, and usually for at least ten years.² Assessment of bone mineral density (to monitor the adverse effects of corticosteroid treatment) should also be considered,² however, regular bone mineral scans may not be available in all areas of New Zealand.

Relapse is common in people with giant cell arteritis

Relapse of symptoms is relatively common in people with giant cell arteritis, particularly once the dose of prednisone is low, e.g. under 15 mg per day. Relapse should be suspected in patients with a return of symptoms, ischaemic complications, unexplained fever or polymyalgic symptoms.² Relapse is managed by increasing the dose of prednisone (Table 1).

If patients have three or more relapses or the dose of prednisone is unable to be tapered without complications, discuss with an Ophthalmologist or Rheumatologist. In some cases, adjunctive treatments such as methotrexate may be considered.


 For further information on the use of methotrexate, see "Polymyalgia rheumatica", Page 24.

Table 1: The signs of potential relapse of giant cell arteritis and recommended treatment¹²

Signs	Recommended treatment
A giant cell arteritis-suggestive headache	Treat with the previous dose of prednisone, i.e. if the dose is lowered to 10 mg daily, and headaches occur, move dose back to 12.5 mg daily
Jaw claudication, with or without headache	Return to 60 mg daily, and begin taper again
Visual symptoms	Treat with 60 mg prednisone and arrange ophthalmology referral

Prognosis for people with giant cell arteritis

The majority of patients respond rapidly to the initial treatment with prednisone, and visual loss in treated patients (without preceding visual symptoms) is rare, generally under 1%.^{2,7} A treatment course of two to three years is often necessary, with some patients requiring low-dose prednisone for several years thereafter.² Corticosteroid-related adverse effects are therefore common, occurring in approximately 60% of patients.⁷ Major risks include the development of diabetes mellitus and osteoporotic fractures.² Patients should be informed of these adverse effects and may need to be advised to make lifestyle changes to lower their risk of these complications.

The mortality rate of people with giant cell arteritis is not significantly different from the general population.⁷ However, the risk of aortic aneurysm is reported to be 17 times greater in people who have had giant cell arteritis, when compared to the general population of the same age and sex, even after timely and successful treatment.⁷ Annual monitoring with chest x-ray and ultrasound, and the management of modifiable risk factors, such as hypertension, smoking and central obesity, will help to reduce this risk.

ACKNOWLEDGEMENT Thank you to **Dr Logan Mitchell**, Consultant Ophthalmologist, Dunedin Hospital, Senior Lecturer, Dunedin School of Medicine, University of Otago and **Associate Professor Andrew Harrison**, Rheumatologist, Clinical Head of Department, Wellington Regional Rheumatology Unit and Wellington School of Medicine, University of Otago, Wellington for expert review of this article.

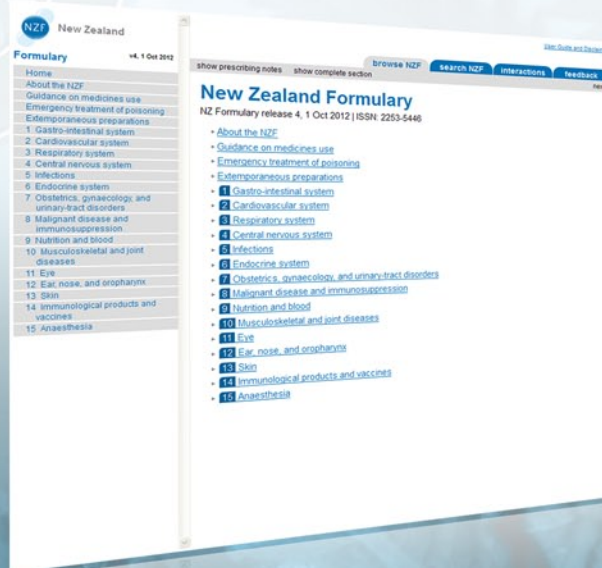References

1. Watts R, Scott D. Epidemiology of the vasculitides. *Semin Respir Crit Care Med.* 2004;25(5):455–64.
2. Dasgupta B, Borg F, Hassan N, et al. BSR and BHPR guidelines for the management of giant cell arteritis. *British Society for Rheumatology*; 2010. Available from: www.rheumatology.org.uk (Accessed May, 2013).
3. Ly K-H, Regent A, Tamby M, Mouthon L. Pathogenesis of giant cell arteritis: More than just an inflammatory condition? *Autoimmun Rev.* 2010;9(10):635–45.
4. Abdul-Rahman A, Molteno A, Bevin T. The epidemiology of giant cell arteritis in Otago, New Zealand: a 9-year analysis. *N Z Med J.* 2011;124(1329):44–52.
5. Salvarani C, Cantini F, Hunder G. Polymyalgia rheumatica and giant-cell arteritis. *The Lancet.* 2008;9634:234–45.
6. Cornblath W, Eggenberger E. Progressive visual loss from giant cell arteritis despite high-dose intravenous methylprednisolone. *Ophthalmology.* 1997;104(5):854–8.
7. BMJ Best Practice. Giant cell arteritis. *BMJ*; 2013. Available from: <http://bestpractice.bmj.com/best-practice/monograph/177.html> (Accessed Jun, 2013).
8. Kermani T, Warrington K, Crowson C, et al. Large-vessel involvement in giant cell arteritis: a population-based cohort study of the incidence-trends and prognosis. *Ann Rheum Dis.* 2012;00:1–6.
9. Danesh-Meyer H, Savino P, Gamble G. Poor prognosis of visual outcome after visual loss from giant cell arteritis. *Ophthalmology.* 2005;112(6):1098–103.
10. Mackie S, Pease C. Diagnosis and management of giant cell arteritis and polymyalgia rheumatica: Challenges, controversies and practical tips. *Postgrad Med J.* 2013;89:284–92.
11. Warrington K, Matteson E. Management guidelines and outcome measures in giant cell arteritis (GCA). *Clin Exp Rheumatol.* 2007;25(Suppl 47):137–41.
12. Dasgupta B, Turner-Stokes L, Higgins B, Turner-Stokes T. Diagnosis and management of giant cell arteritis. *Royal College of Physicians*; 2010. Available from: www.rcplondon.ac.uk (Accessed May, 2013).
13. Hoes J, Jacobs J, Boers M, et al. EULAR evidence-based recommendations on the management of systemic glucocorticoid therapy in rheumatic diseases. *Ann Rheum Dis.* 2007;66(12):1560–7.

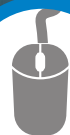NZF New Zealand Formulary

The New Zealand Formulary

- Easily navigated and searchable medicines information.
- Adapted from the British National Formulary incorporating Pharmac and Medsafe information.
- Additional information from reputable sources (e.g. drug interactions, drugs in pregnancy, breastfeeding).
- Indications and doses reflect current New Zealand practice.
- Updated monthly and freely available to all healthcare professionals within New Zealand.



Get started today



Visit: www.nzformulary.org