

# A five minute back examination with neurological assessment

Adapted from Cameron 2009<sup>1</sup>

Also available online at [www.bpac.org.nz](http://www.bpac.org.nz)

Ask the patient to remove enough clothing to allow full inspection of the back and legs.

## With the patient standing:

- Inspect the spine for any developmental or traumatic deformities. Assess the lumbar lordosis; loss of curvature may indicate ankylosing spondylitis. Look for any muscle wasting (buttock, thigh, calf). Check for any discrepancy in leg length by comparing the levels of the iliac crests.
- Movement: Ask the patient to extend the spine, flex forward and then flex laterally by sliding their palm down their outer thigh. Most patients with non-specific back pain will be slightly stiff in extension, have pain on flexion, and asymmetric limitation and pain on lateral flexion.

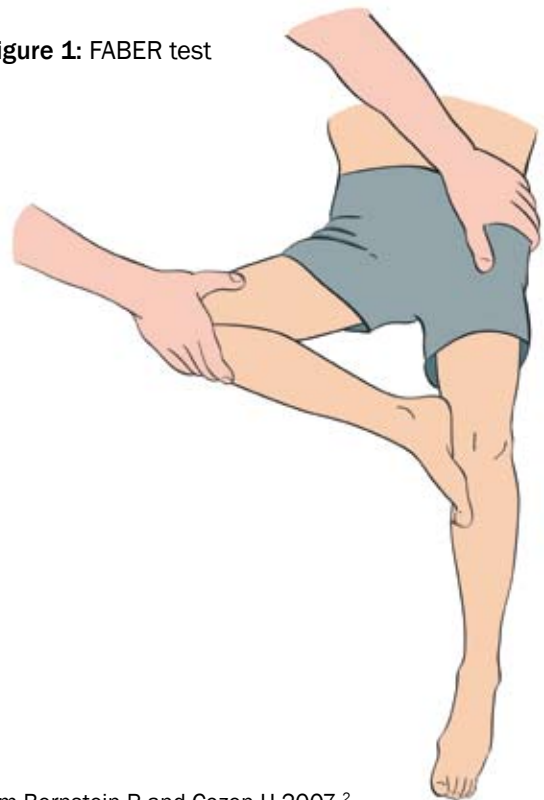## With the patient lying supine

1. Rule out other joint involvement: check the hip joints for range of movement and pain. Perform stress test on sacro-iliac joints (e.g. FABER test), especially in young patients.
2. Test the nerve roots: Straight leg raise test. This stretches nerve roots L4, L5 and S1. Pick the leg up by the ankle. While keeping the knee fully extended, lift the leg up towards ninety degrees or beyond (Figure 2). If the patient has significant nerve root entrapment shooting leg pain will be reproduced before you get much beyond thirty degrees of elevation. Back pain produced by straight leg raising is common and does not always indicate nerve root involvement.

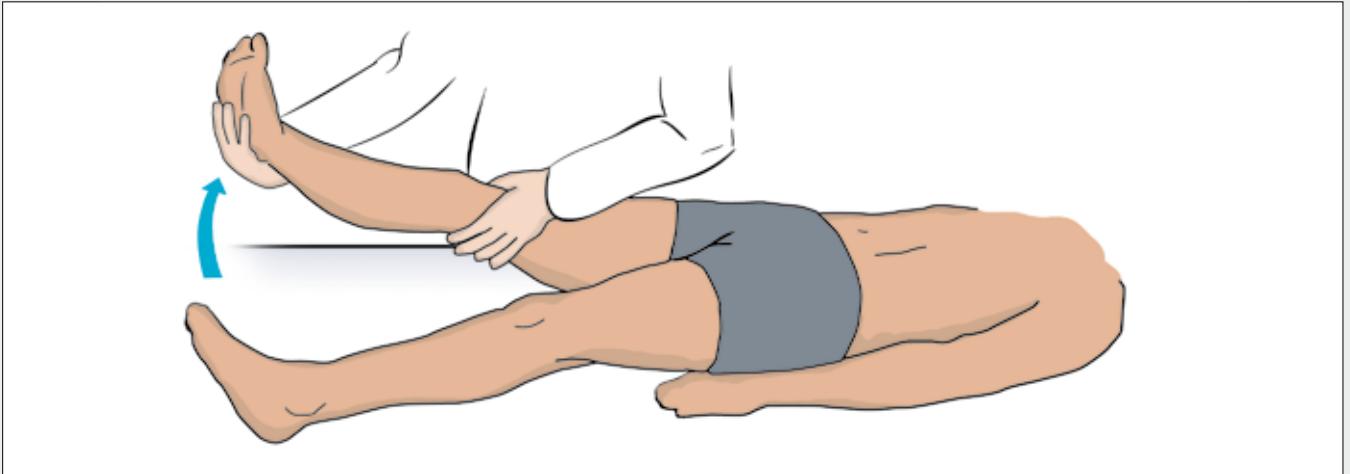
## The FABER test

The Flexion, Abduction, and External Rotation (FABER) test is used to detect hip or sacro-iliac joint problems. The patient lies in a supine position, and the foot is placed on the opposite knee; in this position groin pain indicates a hip problem rather than a spinal problem. The doctor then presses on the flexed knee and on the opposite anterior superior iliac crest; pain in the sacroiliac area indicates a problem with sacroiliac joints (Figure 1).

Figure 1: FABER test



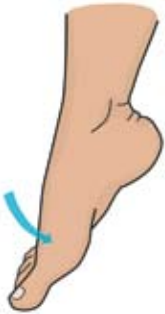


from Bernstein R and Cozen H 2007 <sup>2</sup>



**Figure 2:** Straight leg raise test




3. Assess muscle power

Muscle group	Nerve root
Resisted flexion of hip	L2 and L3
Resisted knee flexion	S2
 <p>Resisted dorsiflexion of the ankle</p>	L4
 <p>Resisted extension of the big toe</p>	L5
 <p>Resisted eversion of the foot or resisted plantar flexion of the ankle</p>	S1

4. Check the reflexes

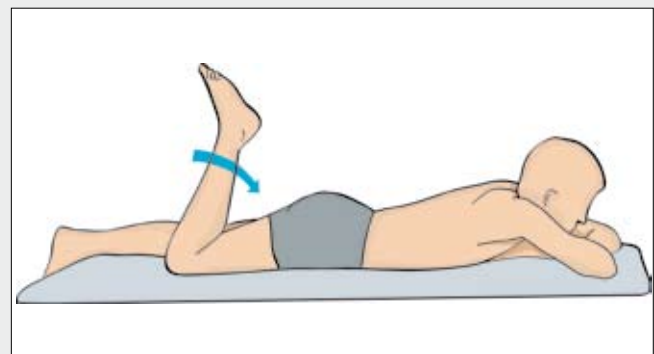
Reflex	Nerve root
Knee jerk	L3 and L4
Ankle jerk	L5 and S1
Plantar reflex	Up-going toes in adults may indicate upper motor neurone abnormalities such as myelopathy or demyelinating disease, rather than common low back problem.

5. Check for skin sensory loss

Disk	L3-L4	L4-L5	L5-S1
Nerve root	L4	L5	S1
Sensory loss signature zone	Medial malleolus 	Dorsal third metatarsophalangeal joint 	Lateral heel 

**With the patient lying prone**

- Femoral nerve stretch test (nerve roots L2, L3 and L4): With the patient lying prone, flex the knee towards ninety degrees (Figure 3). Burning discomfort in the groin or anterior thigh will occur if there is femoral nerve involvement.
- Palpate the spine for tenderness and for muscle spasm



**Figure 3:** Femoral nerve stretch test

**With the patient on their side**

In patients who describe loss of sphincter control, or with serious or progressive neurological findings, test for impaired sensation in the saddle area (checking pin-prick sensation around the anus) and assess anal sphincter tone by digital examination while the patient tries to “squeeze” your examining finger.

**References:**

1. Cameron G. The assessment of lower back pain in primary care or family practice. Available from: [www.jointenterprise.co.uk/backpain-1.htm](http://www.jointenterprise.co.uk/backpain-1.htm) (accessed April 2009).
2. Bernstein R, Cozen H. Evaluation of back pain in children and adolescents. AAFP 2007;76(11):1669-76.